evidence & experience

Laryngectomy Peristomal Skin:
Assessment, Intervention & Monitoring (AIM) Guide

Healthy peristomal skin is a pre-requisite for optimal medical adhesive use in total laryngectomy patients. It creates the foundation for adherent HME use, which leads to improved pulmonary health and facilitates tracheoesophageal voicing.[1]

The AIM Guide was developed to provide a common language to describe skin complications seen under the adhesive baseplate and to provide practical care guidance to help promote early intervention and minimize Medical Adhesive-Related Skin Injuries (MARSI).

Prevention is better than cure; AIM to keep the skin healthy and intact.

Scan the QR code to read a whitepaper Healthy Peristomal Skin for more information on preventable causes of MARSI and possible solutions

Acknowledgment

We would like to thank Prof Dr Rustemeyer for reviewing the content of this Laryngectomy Peristomal Skin AIM Guide.



Prof Dr Thomas Rustemeyer

Thomas Rustemeyer is professor in dermato-allergology and occupational dermatology at the Department of Dermatology-Allergology at the Amsterdam University Medical Centers, the Netherlands.

He is supervisor of immunological research of the University, and he is active in supervising patient's care and research addressing fundamental immunological and translational research topics. He is (co)author of more than 300 publications and editor of several textbooks. He is member and/or chairperson of various national land international societies active in dermato-allergology, immunology and occupational health, including governmental and regulatory affairs.

MARSI Mechanical Trauma

Trauma that can occur after removing an adhesive incorrectly. Skin stripping removes one or more of the top layers of the epidermis. Lesions are typically shallow and irregular, skin may appear shiny, and lesions may be red (erythema) or show blister formation. [2, 3, 4, 5]

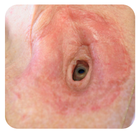

MARSI Chemical Irritation

Irritant contact dermatitis is an inflammatory skin response to chemical irritants that can cause dryness, scaling, cracking, redness, swelling, and increased skin permeability. The condition disturbs the skin's pH balance, which normally protects the skin from pathogens and damage by certain chemical compounds. Irritant contact dermatitis is non-allergic and commonly resolves shortly after the chemical exposure is cleared. However, the reaction may persist for weeks after exposure to the irritant. [6,7]



Irritant contact dermatitis

Allergic dermatitis is an immunological reaction in the area exposed to an allergen, for example, an adhesive component or accessory. Allergic contact dermatitis presents with redness and blisters in the area exposed to the allergen and beyond, which in turn, increases skin permeability. This type of skin reaction may be associated with other underlying allergies.[6,8]

MARSI Maceration

Skin damage that can occur from prolonged accumulation of moisture under an adhesive baseplate (mucus/wound discharge/sweat). When exposed to high levels of moisture the skin will become soft, pale, swollen and wrinkled. Maceration increases skin permeability and makes the skin more susceptible to infection and damage from friction and irritants. [9]



Radiation Dermatitis

Radiation dermatitis is a major side effect associated with radiation exposure and exists on a continuum ranging from erythema to moist desquamation. 95% of patients receiving radiation therapy will develop some form of radiation dermatitis including erythema, dry desquamation and moist desquamation. [10]



Visual symptoms	Care guidance
Intact Injured Skin • Redness • Shiny skin • Dry / tight skin • Blister formation • Discomfort	Assess correct adhesive application and removal techniques are being used to prevent skin stripping Avoid washing the skin too much. Use Provox Cleaning Towel, pH-balanced soap subsitute or just warm water. Allow to completely dry [11] Use a barrier wipe and allow to fully dry before applying an adhesive Switch to a Provox Life Sensitive Adhesive (hydrocolloid), skin friendly choice Introduce Provox Life Night Adhesive (hydrogel) to improve skin recovery overnight Avoid repeated adhesive changes. Schedule routine adhesive changes that allow for properly prepared changes in hygienic conditions Assess skin daily between adhesive changes. If skin continues to deteriorate - stop using adhesives
Non-Intact Injured Skin • Significant redness • Skin tear (layers of skin separate) • Bleeding • Significant pain and discomfort • Increased risk of bacterial infection due to breached skin	Stop using an adhesive Switch to a laryngectomy tube or stoma button with an HME Monitor for signs of infection (e.g. increasing redness, swelling, warmth, burning sensation, pain) and seek medical advice

Visual symptoms	Care guidance
Irritant contact dermatitis • Redness and swelling • Dry cracked skin • Rash • Small blisters sometimes with oozing and crusting • Burning and stinging often immediately after exposure to the irritant • **Immediate onset:** symptoms typically appear within minutes or hours of exposure • **Defined border** to the site of the adhesive placement **Allergic contact dermatitis** • Redness and swelling • Rash • Small blisters sometimes with oozing and crusting • Itching is a predominant symptom • **Delayed onset:** symptoms typically appear 24-48 hours after exposure • **Non-defined border** to the site of adhesive placement or allergen exposure	Remove the adhesive and use a pH-balanced soap substitute or just warm water water to remove any adhesive residue. Allow to completely dry Apply cool gauze, allow to dry and then apply a barrier cream. If no improvement seen and the inflammation and itching persists, seek medical consultation to consider topical steroids [11] Assess adhesive care routine. Discontinue products that may be causing the skin reaction Has a patch test been carried out to identify any unknown allergies? Consider referral to dermatology department for patch test and advice Switch to laryngectomy protective cover until skin healed and seen by a dermatologist or irritant / allergen has been identified Monitor and seek medical advice if signs of infection occur (e.g. increasing redness, swelling, warmth, burning sensation, pain)

Visual symptoms	Care guidance
Intact Injured Skin • Skin lighter in color, wrinkled • Skin soft, swollen and damp • Increased risk of fungal infection due to moist / warm environment	Assess correct adhesive application and removal techniques are being used to prevent further damage Avoid washing the skin too much. Use Provox Cleaning Towel, pH-balanced soap subsitute or just warm water. Allow to completely dry [2] Use a barrier wipe and allow to fully dry before applying an adhesive Switch to a Provox Life Sensitive Adhesive (hydrocolloid), to help manage excess moisture. Do not allow moisture to sit under an adhesive for prolonged periods of time. When the hydrocolloid is white it has fully absorbed excess moisture and needs changing Do not allow mucus from coughing to settle at the bottom of the stoma and seep underneath the adhesive. After a productive cough, secretions must be removed from this area Assess skin daily between adhesive changes. If skin continues to deteriorate - stop using adhesives
Non-Intact Injured Skin • Blistered or eroded skin • Increased pain or burning sensation • Increased risk of of fungal infection due to moist / warm environment	Stop using an adhesive Switch to a laryngectomy tube or stoma button and HME Monitor for signs of infection (eg increasing redness, swelling, warmth, burning sensation, pain) and seek medical advice

Visual symptoms	Care guidance
Erythmea (redness around treatment field) • Dry skin, may feel tighter • Intensifies with treatment **Dry desquamation** • Flaky / dry skin • Itching (New cells produce faster than damaged cells are removed, resulting in scaly / thickened skin)	Switch to a Provox Life Sensitive Adhesive (hydrocolloid), skin friendly choice Gentle daily skincare. Use a-pH balanced soap substitute or just warm water to avoid drying the skin. Allow to completely dry Apply a non-fragranced, alcohol free moisturizer regularly. Do not apply immediately before treatment If required seek medical advice for treatment to relieve itching and / or pain Assess correct adhesive application and removal techniques are being used to prevent skin stripping Introduce Provox Life Night Adhesive (hydrogel) to soothe the skin and provide comfort
Moist desquamation • Blistering and skin breakdown • Moist, edematous skin • Exudate may be present • Significant pain and discomfort	Stop using an adhesive Seek medical advice for appropriate dressings / products for broken skin, and ongoing pain management Monitor and seek medical advice if signs of infection occur (e.g. increasing redness, swelling, warmth, burning sensation, pain)

References:

1. Atos Medical, Whitepaper: Healthy peristomal skin: a foundation for successful voice and pulmonary rehabilitation, 2023.
2. Fumarola S, Allaway R, Callaghan R, Collier M, Downie F, Geraghty J, Kiernan S, Spratt F. Overlooked and underestimated: medical adhesive-related skin injuries. Best practice consensus document on prevention. J Wound Care 2020; 29(Suppl 3c):S1–S24.
3. Cutting KF. Impact of adhesive surgical tape and wound dressings on the skin, with reference to skin stripping. J Wound Care. 2008;17(4):157-8, 60-2.
4. Blaylock B, Murray M, O'Connell K, Rex J. Tape injury in the patient with total hip replacement. Orthopedic nursing. 1995;14(3):25-8.
5. Brett DW. Impact on Pain Control, Epidermal Stripping, Leakage of Wound Fluid, Ease of Use, Pressure Reduction, and Cost- Effectiveness. Journal of Wound Ostomy & Continence Nursing. 2006;33:S15-S9.
6. Conway J, Whettam J. Adverse reactions to wound dressings. Nurs Stand. 2002;16(44):52-4, 6, 8 passim.
7. Widman TJO, Holly. Storrs, Frances J. Allergic contact dermatitis from medical adhesive bandages in patients who report having a reaction to medical bandages. Dermatitis. 2007;18(2):103.
8. Norris P, Storrs FJ. Allergic contact dermatitis to adhesive bandages. Dermatol Clin. 1990;8(1):147-52.
9. McNicol L, Lund C, Rosen T, Gray M. Medical Adhesives and Patient Safety: Consensus Statement for the Assessment, Prevention and Treatment of Adhesive-Related Skin Injuries. Journal of Wound, Ostomy and Continence Nursing. 2014;40(4):365-80.
10. Singh M, Alavi A, Wong R, Akita S. Radiodermatitis: A Review of Our Current Understanding. Am J Clin Dermatol. 2016 Jun;17(3):277-92.
11. Hitchcock J, Haigh DA, Martin N, Davies S. Preventing medical adhesive-related skin injury (MARSI). Br J Nurs. 2021 Aug 12;30(15):S48-S56.
12. Madeleine Flanagan: Wound Healing and Skin Integrity, Wiley-Blackwell, 2013, page 34, ref to Enoch and Leaper, 2005.

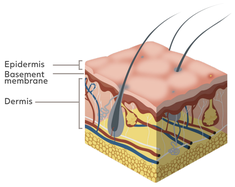

Definitions

Intact Injured Skin (superficially injured skin): presents with superficial pathological changes or changes following disease or trauma but where the basement membrane is unbroken. [12]
Non-intact injured skin (breached): is skin presenting pathological changes or changes following disease or trauma where the basement membrane is breached. [12]

Scan the QR code to read a Correct removal and application techniques of adhesives:

The information presented should not be considered medical advice for specific conditions. A patient's individual circumstances and preferences should always be considered and clinical practice should be in accordance with the principles of protection, participation and partnership

Always read the Instructions for Use before starting to use any of the products. For Instructions for Use, please visit www.atosmedical.com
Atos and the Atos logo are trademarks of Coloplast A/S. © 2025 Coloplast A/S. All rights reserved

Atos

PM36363_ThEN_202501