evidence
& experience

Laryngectomy Peristomal Skin:

Assessment, Intervention & Monitoring AIM Guide

Healthy peristomal skin is a pre-requisite for optimal medical adhesive use in total laryngectomy patients. It creates the foundation for adherent HME use, which leads to improved pulmonary health and facilitates tracheoesophageal voicing.[1]

The AIM Guide was developed to provide a common language to describe skin complications seen under the adhesive baseplate and to provide practical care guidance to help promote early intervention and minimize Medical Adhesive-Related Injuries (MARSI). Prevention is better than cure; AIM to keep the skin healthy and intact.

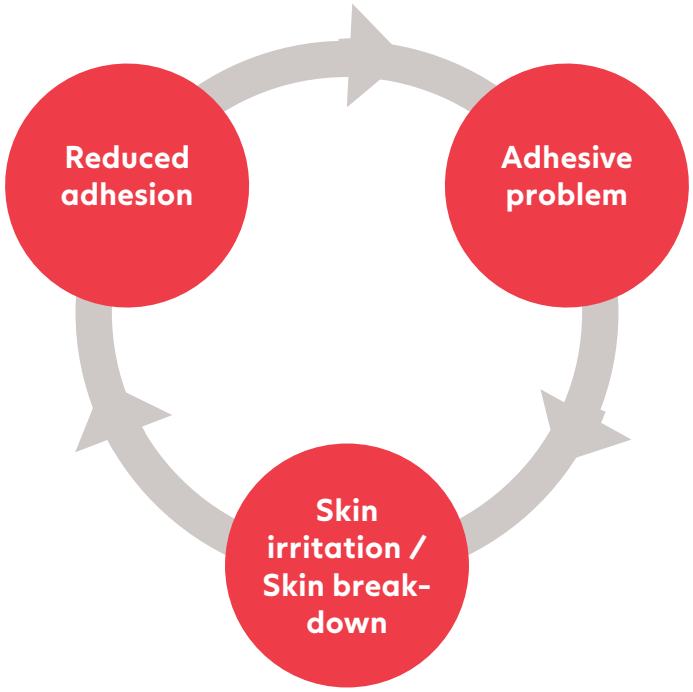

Vicious circle of adhesive problems leading to skin irritation and irritated skin causing further problems with the adhesive not sticking to the skin.

Atos

Support patients to help maintain healthy peristomal skin and minimize MARSI

Identify patients at risk	• Know intrinsic and extrinsic risk factors for MARSI and identify patients who are at risk • Develop a good adhesive routine and closely monitor
Use the most skin-friendly adhesive option	• Hydrocolloids and hydrogels are the most skin-friendly options • A hydrocolloid may be suitable for general use, depending on its ability to withstand phonatory pressure in tracheoesophageal speech speakers
Develop a good adhesive routine	• Develop a routine that allows for planned adhesive changes so that adequate time is available • Identify the need for hydrogel adhesive use for skin care and recovery, developing a schedule towards prevention of MARSI
Apply proper application and removal technique	• Know and understand state of the art for adhesive removal and application • Be meticulous
Make intact peristomal skin a priority	• Monitor and record skin condition • Detect problems early • Refer to dermatologist, if required

Scan the QR code to read a whitepaper Healthy Peristomal Skin for more information on preventable causes of MARSI and possible solutions.

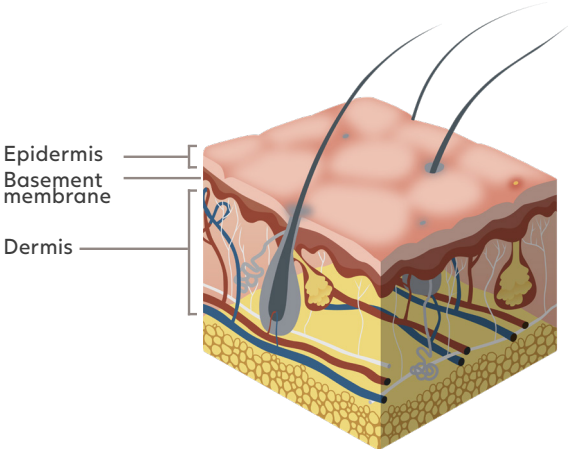

Definitions

Intact Injured Skin (superficially injured skin): presents with superficial pathological changes or changes following disease or trauma but where the basement membrane is unbroken. [2]

Non-Intact Injured-Skin (breached skin): presents with pathological changes or changes following disease or trauma where the basement membrane is breached. [2]

MARSI

Mechanical Trauma

Trauma that can occur after removing an adhesive incorrectly. Skin stripping removes one or more of the top layers of the epidermis. Lesions are typically shallow and irregular, skin may appear shiny, and lesions may be red (erythema) or show blister formation. [3, 4, 5, 6]



Visual symptoms	Care guidance
Intact Injured Skin • Redness • Shiny skin • Dry / tight skin • Blister formation • Discomfort	Assess correct adhesive application and removal techniques are being used to prevent skin stripping
	Avoid washing the skin too much. Use a Provox Cleaning Towel, PH-neutral soap substitute or just warm water to avoid drying the skin. Allow to completely dry [7]
	Use a barrier wipe and allow to fully dry before applying an adhesive
	Switch to a Provox Life Sensitive Adhesive (hydrocolloid), skin friendly choice
	Introduce Provox Life Night Adhesive (hydrogel) to improve skin recovery overnight
	Avoid repeated adhesive changes. Schedule routine adhesive changes that allow for properly prepared changes in hygienic conditions
	Assess skin daily between adhesive changes. If skin continues to deteriorate - stop using adhesives
Non-Intact Injured Skin • Significant redness • Skin tear (layers of skin separate) • Bleeding • Significant pain and discomfort • Increased risk of bacterial infection due to breached skin	Stop using an adhesive
	Switch to a laryngectomy tube or stoma button with an HME
	Monitor for signs of infection (eg increasing redness, swelling, warmth, burning sensation, pain) and seek medical advice

MARSI

Chemical Irritation

Irritant contact dermatitis is an inflammatory skin response to chemical irritants that can cause dryness, scaling, cracking, redness, swelling, and increased skin permeability. The condition disturbs the skin's pH balance, which normally protects the skin from pathogens and damage by certain chemical compounds. Irritant contact dermatitis is non-allergic and commonly resolves shortly after the chemical exposure is cleared. However, the reaction may persist for weeks after exposure to the irritant. [8, 9]



Irritant contact dermatitis

Allergic dermatitis is an immunological reaction in the area exposed to an allergen, for example, an adhesive component or accessory. Allergic contact dermatitis presents with redness and blisters in the area exposed to the allergen and beyond, which in turn increases skin permeability. This type of skin reaction may be associated with other underlying allergies. [8, 10]

Visual symptoms

Irritant contact dermatitis

- Redness and swelling
- Dry cracked skin
- Rash
- Small blisters, sometimes with oozing and crusting
- Burning and stinging often immediately after exposure to the irritant
- **Immediate onset:** symptoms typically appear within minutes or hours of exposure
- **Defined border** to the site of the adhesive placement

Allergic contact dermatitis

- Redness and swelling
- Rash
- Small blisters sometimes with oozing and crusting
- Itching is a predominant symptom
- **Delayed onset:** symptoms typically appear 24-48 hours after exposure
- **Non-defined border** to the site of adhesive placement or allergen exposure

Care guidance

Switch to a Provox Life Sensitive Adhesive (hydrocolloid), skin friendly choice

Remove the adhesive and use pH-balanced soap substitute or just warm water to remove any adhesive residue. Allow to completely dry

Apply cool gauze, allow to dry and then apply a barrier cream. If no improvement seen and the inflammation and itching persists, seek medical advice to consider topical steroids. [7]

Assess adhesive care routine. Discontinue products that may be causing the skin reaction

Has a patch test been carried out to identify any unknown allergies? Consider referral to dermatology department for patch test and advice

Switch to laryngectomy protective cover until skin has healed and seen by a dermatologist or irritant / allergen identified

Monitor and seek medical advice if signs of infection occur (e.g. increasing redness, swelling, warmth, burning sensation, pain)

MARSI

Maceration

Skin damage that can occur from prolonged accumulation of moisture under an adhesive baseplate (mucus/wound discharge/ sweat). When exposed to high levels of moisture the skin will become soft, pale, swollen and wrinkled. Maceration increases skin permeability and makes the skin more susceptible to infection and damage from friction and irritants.[11]



Visual symptoms	Care guidance
Intact Injured Skin • Skin lighter in color, wrinkled • Skin soft, swollen and damp • Increased risk of fungal infection due to moist / warm environment	Avoid washing the skin too much. Use Provox Cleaning Towel, pH-neutral soap substitute or just warm water. Allow to completely dry [7]
	Use a barrier wipe and allow to fully dry before applying an adhesive
	Switch to a Provox Life Sensitive Adhesive (hydrocolloid), to help manage excess moisture. Do not allow moisture to sit under an adhesive for prolonged periods of time. When the hydrocolloid is white it has fully absorbed excess moisture and needs changing
	Do not allow mucus from coughing to settle at the bottom of the stoma and seep underneath the adhesive. After a productive cough, secretions must be removed from this area
	Assess correct adhesive application and removal techniques are being used to prevent further damage
	Assess skin daily between adhesive changes. If skin continues to deteriorate - stop using adhesives
Non-Intact Injured Skin • Blistered or eroded skin • Increased pain or burning sensation • Increased risk of of fungal infection due to moist / warm environment	Stop using an adhesive
	Switch to a laryngectomy tube or stoma button and HME
	Monitor for signs of infection (e.g. increasing redness, swelling, warmth, burning sensation, pain) and seek medical advice

Radiation Dermatitis

Radiation dermatitis is a major side effect associated with radiation exposure and exists on a continuum ranging from erythema to moist desquamation. 95% of patients receiving radiation therapy will develop some form of radiation dermatitis including erythema, dry desquamation and moist desquamation. [12]



Visual symptoms	Care guidance
Erythmea (redness around treatment field) • Dry skin, may feel tighter • Intensifies with treatment	Assess correct adhesive application and removal techniques are being used to prevent skin stripping
Dry desquamation • Flaky / dry skin • Itching (New cells produce faster than damaged cells are removed, resulting in scaly / thickened skin)	Gentle daily skincare. Use a pH-balanced soap substitute or just warm water to avoid drying the skin. Allow to completely dry Apply a non-fragranced, alcohol free moisturizer regularly. Do not apply immediately before treatment If required, seek medical advice for treatment to relieve itching and / or pain Introduce Provox Life Night Adhesive (hydrogel) to soothe the skin and provide comfort
Moist desquamation • Blistering and skin breakdown • Moist, edematous skin • Exudate may be present • Significant pain and discomfort	Stop using an adhesive Seek medical advice for appropriate dressings / products for broken skin, and ongoing pain management Monitor and seek medical advice if signs of infection occur (e.g. increasing redness, swelling, warmth, burning sensation, pain)

1. Clean

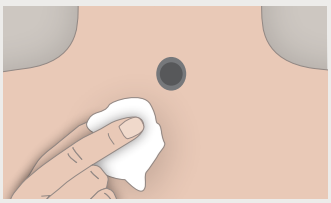

Clean the skin around your stoma with Provox Cleaning Towel, or pH-balanced soap substitute, or just warm water. Ensure the skin is clean and free from mucus, adhesive removers, and creams. Let it dry. When cleaning the skin from residual glue, prevent particles/fluids from entering the stoma.

Tip when cleaning: Trim/shave all hair around the area of application

2. Prepare

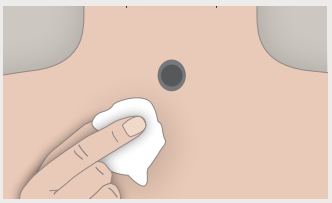

If needed, apply Provox Skin Barrier and let it dry. Provox Skin Barrier leaves a protective layer on your skin.

For Provox Life Night Adhesive, do not use Provox Skin Barrier or products such as soap or skin cream that leave an oily residue on the skin, as they may prevent the Night Adhesive from sticking properly.

Tip when preparing: If you need strong attachment, apply Provox Silicone Glue sparingly. Silicone Glue can not be used with Night Adhesive!

3. Apply



a) Rub the adhesive between your hands to warm it up.

Provox Life Night Adhesive does not benefit from pre-warming

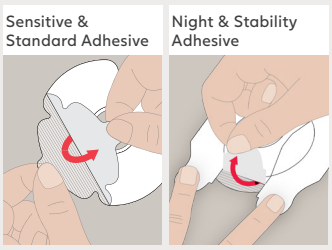

b) Remove the protective paper. For Provox Life Night and Provox Life Stability Adhesive, start by removing the middle liner and then remove the side liners once the middle part is on the skin.

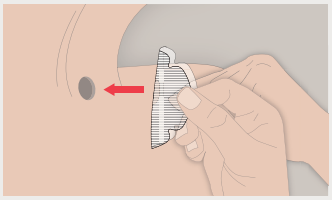

c) Apply the ring of the adhesive as close as possible to the opening of your stoma. Keep your neck in a neutral position, do not pull or stretch the adhesive.

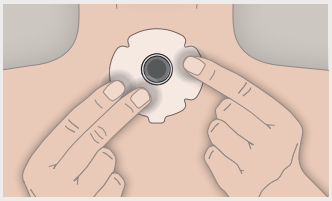

d) Gently massage the adhesive onto your skin. Start from your stoma and gently massage outwards. Finally, massage the entire adhesive.

Tips when applying:

- Avoid gaps and wrinkles that can allow mucus to enter between the adhesive and the skin, causing air leaks.
- Don't speak too soon after applying the adhesive; allow the adhesive to bond to your neck for about 15 minutes if possible.
- Don't touch the sticky adhesive layer when applying it to your neck, as this will reduce the overall adhesion.

4. Remove

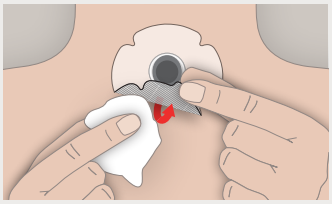

Start at the fingerlift tab and, at a low angle, remove the adhesive slowly and gently, supporting the skin as you peel. For Provox Life Standard and Provox Life Stability Adhesive, first apply Provox Adhesive Remover on top of the adhesive. Then lift the fingerlift tab carefully and add more underneath the adhesive.

Remove the Provox Life Night Adhesive by using a wet cloth. Make sure no water drips into your stoma.

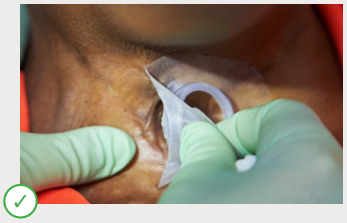



Tip: Slow and gentle removal with a low-angle peel direction and finger support at the peel line, supported with adhesive remover wipes when indicated.

Tips and Tricks for an airtight seal

- Try not to speak too loudly or with too much force
- Remove the HME from the adhesive when you begin to cough
- Always hold the adhesive in place with 2 fingers when removing the HME
- After coughing, carefully remove the mucus and do not allow the mucus to seep underneath the adhesive

Acknowledgment

We would like to thank Prof Dr Rustemeyer for reviewing the content of Laryngectomy Peristomal Skin AIM Guide.



Thomas Rustemeyer is professor in dermato-allergology and occupational dermatology at the Department of Dermatology-Allergology at the Amsterdam University Medical Centers, the Netherlands. He is supervisor of immunological research of the university, and he is active in supervising patient's care and research addressing fundamental immunological and translational research topics. He is (co)author of more than 300 publications and editor of several textbooks. He is member and/ or chairperson of various national land international societies active in dermato-allergology, immunology and occupational health, including governmental and regulatory affairs.

Prof Dr Thomas Rustemeyer

References:

1. Atos Medical, Whitepaper: Healthy peristomal skin: a foundation for successful voice and pulmonary rehabilitation, 2023.

2. Madeleine Flanagan: Wound Healing and Skin Integrity, Wiley-Blackwell, 2013, page 34, ref to Enoch and Leaper, 2005.

3. Fumarola S, Allaway R, Callaghan R, Collier M, Downie F, Geraghty J, Kiernan S, Spratt F.
Overlooked and underestimated: medical adhesive-related skin injuries. Best practice consensus document on prevention. J Wound Care 2020; 29(Suppl 3c):S1–S24.

4. Cutting KF. Impact of adhesive surgical tape and wound dressings on the skin, with reference to skin stripping. J Wound Care. 2008;17(4):157-8, 60-2.

5. Blaylock B, Murray M, O'Connell K, Rex J. Tape injury in the patient with total hip replacement. Orthopedic nursing. 1995;14(3):25-8.

6. Brett DW. Impact on Pain Control, Epidermal Stripping, Leakage of Wound Fluid, Ease of Use, Pressure Reduction, and Cost-Effectiveness. Journal of Wound Ostomy & Continence Nursing. 2006;33:S15-S9.

7. Hitchcock J, Haigh DA, Martin N, Davies S. Preventing medical adhesive-related skin injury (MARSI). Br J Nurs. 2021 Aug 12;30(15):S48-S56.

8. Conway J, Whettam J. Adverse reactions to wound dressings. Nurs Stand. 2002;16(44):52-4, 6, 8 passim.

9. Widman TJO, Holly. Storrs, Frances J. Allergic contact dermatitis from medical adhesive bandages in patients who report having a reaction to medical bandages. Dermatitis. 2007;18(2):103.

10. Norris P, Storrs FJ. Allergic contact dermatitis to adhesive bandages. Dermatol Clin. 1990;8(1):147-52.

11. McNicol L, Lund C, Rosen T, Gray M. Medical Adhesives and Patient Safety: Consensus Statement for the Assessment, Prevention and Treatment of Adhesive-Related Skin Injuries. Journal of Wound, Ostomy and Continence Nursing. 2014;40(4):365-80.

12. Singh M, Alavi A, Wong R, Akita S. Radiodermatitis: A Review of Our Current Understanding. Am J Clin Dermatol. 2016 Jun;17(3):277-92.

The information presented should not be considered medical advice for specific conditions.
A patient's individual circumstances and preferences should always be considered and clinical practice should be in accordance with the principles of protection, participation and partnership

PM37562_202504

Atos and the Atos logo are trademarks of Coloplast A/S. © 2025 Coloplast A/S. All rights reserved